



# Foveal and Retinal Nerve Fiber Layer Thickness in Children With a History of Retinopathy of Prematurity Treated With Bevacizumab: A Cross-sectional Study

Amir Eftekhari Milani<sup>1</sup>, Bahareh Javani<sup>1,2</sup>, Mohamadhosein Ahoor<sup>1</sup>, Mehdi Abdi Shahshahani<sup>1</sup>, Fereshteh Farhadi<sup>1,2,3\*</sup>

## Abstract

**Objectives:** This study aimed to investigate the effects of bevacizumab (an anti-VEGF antibody) on the structure of retina such as the thickness of the nerve fiber layer and macula with optical coherence tomography (OCT) in retinopathy of prematurity (ROP) patients.

**Methods:** This cross-sectional study was conducted in 2021-2022 in Tabriz, Iran to investigate preterm children aged 4-6 years. To this end, a total of 300 eyes of 150 children were assigned to three groups and then were examined by performing Fundus examination of retina, eye refraction test, and OCT imaging. The first group included 100 eyes with a history of ROP and treated with bevacizumab, the second group consisted of 100 eyes with a history of ROP but improved spontaneously, and the third group comprised 100 eyes of preterm children without a history of ROP.

**Results:** Foveal thickness was  $235.46 \pm 11 \mu\text{m}$  in the group receiving bevacizumab,  $267.70 \pm 12 \mu\text{m}$  in the group with spontaneous improvement of ROP, and  $269.48 \pm 10 \mu\text{m}$  in the group with no ROP. Therefore, the mean thickness of the fovea in the group receiving bevacizumab was significantly lower than that in the other two groups. In the group receiving bevacizumab, moreover, the thickness of the nerve layer of the retina was less than that in the other two groups ( $P < 0.005$ ).

**Conclusions:** In sum, a greater understanding of the development of premature fovea was achieved, which may have facilitated identifying the possible clinical and long-term effects of these abnormal changes on adulthood visual acuity. It was recommended that further studies should be carried out to compare laser-treated eyes in order for expanding the scientific understanding of the development of premature fovea and other aspects of ROP, which may have decreased the preventable blindness rate.

**Keywords:** Retinopathy of prematurity, Bevacizumab, Foveal thickness, RNFL thickness

## Introduction

Retinopathy of prematurity (ROP) is a vascular and vasoproliferative disorder in preterm infants. In this disease, new blood vessels and fibrovascular tissue are created in the peripheral retina, which is avascular, by mediators of angiogenesis. The immature retinas of preterm neonates are susceptible to insults that disrupt vascular growth, leading to ROP (1, 2).

Retinopathy caused by prematurity is one of the main causes of vision loss in which low birth weight and prematurity are strongly associated with an increased risk of the disease (2).

ROP is becoming a major cause of potentially preventable blindness among children in middle-income countries that have provided neonatal intensive-care services for preterm and low-birth weight infants (3). According to a study carried out in USA and Canada in 2018, more than 40% of at-risk premature infants developed some stage of ROP which mostly regressed without treatment, whereas nearly 12.5% of them developed severe ROP, which occurs

among infants with low birth weight under 1251 g (4, 5).

The management of ROP has been improving. Screening and treatment interventions include frequent retinal examinations of at-risk preterm infants, laser treatment of the peripheral avascular retina in eyes with severe ROP, as well as intravitreal injection of anti-VEGF (vascular endothelial growth factor) such as bevacizumab in the early stages or prior to retinal detachment and visual rehabilitation (2).

Bevacizumab Eliminates the Angiogenic Threat of ROP trial (BEAT-ROP) was one of the earliest trials indicating the effectiveness of intravitreal bevacizumab (IVB) in the management of Zone I or posterior Zone II ROP and showed decrease in the recurrence of disease in Zone I compared to laser treatment (6).

Kang et al investigated the anatomical effects, benefits, and safety of ROP treatment with Anti-VEGF in South Korea, and showed that the Stage of ROP had greater effect on the complications of the disease than the type of the administered drug, and that anti-VEGFs were

Received 7 October 2022, Accepted 10 February 2023, Available online 3 March 2023

<sup>1</sup>Nikookari Eye Center, Tabriz University of Medical Sciences, Tabriz, Iran. <sup>2</sup>Student Research Committee, Tabriz University of Medical Sciences, Tabriz, Iran. <sup>3</sup>Research Center for Evidence-based Medicine, Iranian EBM Centre: A JBI Centre of Excellence, Faculty of Medicine, Tabriz University of Medical Sciences, Tabriz, Iran.

\*Corresponding Author: Fereshteh Farhadi, Tel: +989194178400, Email: fereshteh\_farhadi@yahoo.com



## Key Messages

- ▶ This study investigated macular and RNFL thickness in bevacizumab-treated eyes with history of ROP, which was not directly measured by previous studies. It also compared ROP eyes treated with bevacizumab with spontaneously-improved eyes.
- ▶ The findings of this study facilitated understanding of the premature fovea, which may have cleared the way for identifying the possible clinical and long-term effects of these abnormal changes on adulthood visual acuity.
- ▶ It was recommended that the laser-treated eyes should be investigated separately in order to extend our understanding of the development of premature fovea and other aspects of ROP as well as to prevent blindness.

relatively safe and reliable drugs with few complications resulted from the treatment of ROP (7). Fukushima et al in Japan combined laser photocoagulation and bevacizumab treatments to treat severe ROP, and achieved favorable anatomical and functional effects (8). Several studies also demonstrated that anti-VEGF therapy could play a promising role in the current treatment of ROP (9-11).

Miki et al examined the size of the foveal avascular zone (FAZ) area of the retina in relation to the thickness and structure of the fovea in preterm infants by adopting optical coherence tomography angiography (OCTA), and found that patients treated with laser had the smallest size of the FAZ area and the largest thickness of the macula in comparison to preterm children with no history of ROP and full-term children. The smaller size of the FAZ area is associated with the presence of greater foveal thickness as well as the presence of inner retinal layer at the fovea and lower gestational age (12).

Considering that during the examination of a large number of premature infants with ROP treated with bevacizumab, we noticed paleness of the optic disc. Distinguishing the presence of glaucoma and its effect on optic disc due to intraocular pressure rise after IVB injection normal IOP (intra ocular pressure) patients entered the study. Although bevacizumab is an anti-VEGF drug, there is a possibility that it affects the normal development of the retina. Since it is off-label drug for ROP and not approved by FDA, this study aimed to investigate the effects of bevacizumab on the structure of retina such as thickness of the nerve fiber layer and macula with OCT in ROP patients.

## Materials and Methods

### Participants

This cross-sectional study was carried out in 2021-2022 to investigate the preterm children aged 4-6 years who had visited the ROP clinic of Nikookari eye hospital in Tabriz, Iran between 2015-2017 for the diagnosis and treatment of ROP. The medical records of these patients were extracted, and then the patients were contacted by phone to arrange visits. Systematic random sampling method was adopted

to select the patients.

### Inclusion Criteria

Premature children aged 4-6 years with a history of ROP and treated with bevacizumab, children of the same age with a history of ROP who received no treatment but recovered spontaneously, as well as premature children without a history of ROP were included in the study. All children had gestational age of 32 weeks or less.

### Exclusion Criteria

Children suffering from other types of eye diseases and eye surface disorders, those with history of eye surgery, those with all types of neurological diseases, those with strabismus or amblyopia, those refusing to give informed consent, those treated with laser therapy, those unwilling to cooperate on the examination or preparation of imaging or vision evaluation, those with refractive errors outside the range of -1.00 – +1.00, those with a history of head or neck diseases and treated with radiotherapy or chemotherapy, as well as those with a history of using chemotherapy drugs for reasons of all sorts were excluded from the study.

### Data Procedures

A total of 300 eyes of 150 children were classified into three groups. The first group consisted of 100 eyes with a history of ROP and treated with bevacizumab; the second group included 100 eyes with a history of ROP but improved spontaneously without administering any treatments; and the third group comprised 100 eyes of preterm children without a history of ROP. Sample size was estimated based on previous studies (7, 12).

Ophthalmological examination was conducted on participating children, which included a slit lamp examination, a fundus examination with a dilated pupil and with a 90 lens, eye refraction test was done. Children meeting inclusion criteria were included in the study and OCT imaging was performed in the OCT department of Nikookari hospital in Tabriz by the relevant operators under the same conditions using the OCT device (Heidelberg, Germany).

The thickness (based on micrometers) of the central half-millimeter of the macula and retinal nerve fiber layer (RNFL) in four superior, inferior, temporal, and nasal quadrants were evaluated in children with history of retinopathy and treated with bevacizumab, premature children without retinopathy, and those with history of retinopathy and improved spontaneously.

### Statistical Analysis

The results were analyzed using SPSS software version 21. Chi-square test, *t* test, and their non-parametric equivalents such as Wilcoxon and analysis of variance were used to measure the qualitative and quantitative variables. *P* value less than 0.05 was considered significant.

## Results

### Demographic Information

Out of 150 children (i.e., 300 eyes) included in this study, 50 children (33.33%) had ROP and were treated with bevacizumab, 50 ones (33.33%) had ROP with spontaneous recovery, and other 50 ones were pre-mature with no history of ROP. Out of these 150 children, moreover, 65 ones were female (130 eyes) and 85 ones were male (170 eyes). Fortunately, there were no missing data.

Average gestational age and average refractive error of children in all three groups are shown in Table 1. As it is shown, 19 participants aged four years, 75 participants aged 5 years, and 56 participants aged 6 years.

Although the gestational age of participants needing bevacizumab treatment was lower than that of participants in other two groups, there was no significant difference between them ( $P=0.071$ , as estimated by Wilcoxon test). No significant difference was detected among three groups in terms of average refractive error ( $P=0.096$ , as estimated by Wilcoxon test). Majority of the patients had a very mild refractive error, hyperopia with low astigmatism. And participants with refractive error outside -1 to +1 were excluded from this study. The difference between the group receiving bevacizumab and the group without ROP was statistically significant regarding refractive errors ( $P=0.0013$ , 0.042), but the refractive errors of the group receiving bevacizumab was not significantly different from the group with spontaneous improvement of ROP ( $P=0.099$ , as estimated by Wilcoxon test).

### ROP Stages and Zones

The 200 eyes with history of ROP stages and zones are shown in Table 2. None of them was stage 0 or stage IV. There was a relatively significant difference between these two groups, and the number of eyes with a more advanced stage of ROP was higher in the group receiving bevacizumab ( $P<0.045$ , as estimated by  $t$  test).

As for the zone, ROP was more posterior and closer to the disc and macula in the group receiving bevacizumab ( $P<0.035$ , as estimated by  $t$  test).

Foveal thickness: According to our study results, the average thickness of the central 0.5 mm of the macula (fovea) was  $257.54 \pm 16 \mu\text{m}$  among the three groups. Foveal thickness was  $235.46 \pm 11 \mu\text{m}$  in the group receiving bevacizumab,  $267.70 \pm 12 \mu\text{m}$  in the group

**Table 2.** ROP Stages and Zones

ROP	Spontaneous improving	Bevacizumab treated
Stage	I	61
	II	33
	III	6
Zone	I	0
	II	45
	III	55

with spontaneous improvement of ROP, and  $269.48 \pm 10 \mu\text{m}$  in the group with no ROP. This suggested that the mean thickness of the fovea in the group receiving bevacizumab was significantly lesser than those in other two groups ( $P<0.001$ , as estimated by variance analysis). However, there was no significant difference between two groups without ROP and the group with spontaneous improvement of ROP in terms of foveal thickness ( $P<0.15$ , as estimated by variance analysis). Figure 1 displays an example of lower foveal thickness of both eyes in one of children with history of ROP and bevacizumab injection.

### RNFL Thickness

The average thickness of the RNFL in four quadrants and among three studied groups was calculated as  $94.45 \pm 10 \mu\text{m}$ , which was  $83.05 \pm 10 \mu\text{m}$  in the group receiving bevacizumab,  $95.87 \pm 11 \mu\text{m}$  in the group with spontaneous improvement of ROP, and  $104.43 \pm 10 \mu\text{m}$  in the group without ROP. This was suggestive of a significant difference between the group receiving bevacizumab and other two groups in term of the thickness of RNFL, so that the thickness of the nerve layer of the retina in the group receiving bevacizumab was less than those of other two groups ( $P<0.005$ , as estimated by variance analysis). However, the two groups without ROP and with spontaneous improvement of ROP were not significantly different regarding RNFL thickness ( $P<0.095$ , as estimated by variance analysis).

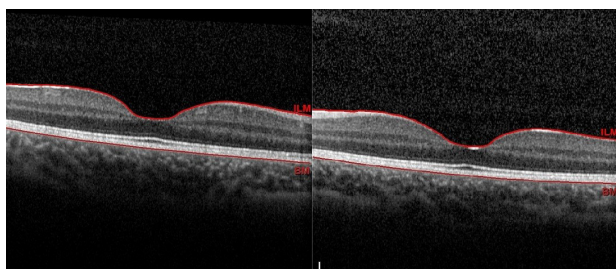
Moreover, it was found that the thickness of RNFL in the temporal quadrant was lesser than those of other quadrants and close to the nasal quadrant, but it was higher in the superior quadrant than those of other quadrants ( $P<0.005$ , as estimated by variance analysis). RNFL thickness of the quadrants is separately shown in Table 3.

### Discussion

**Table 1.** Demographic Information

	Eyes	Number of Subjects	Male	Female	GA (w) (Mean $\pm$ SD)	RE (Mean $\pm$ SD)
Spontaneous improving	100	50	23	27	28.3 $\pm$ 2.1	+0.50 $\pm$ 0.25
Without ROP	100	50	34	16	28.1 $\pm$ 3.2	+0.62 $\pm$ 0.25
ROP treated with bevacizumab	100	50	23	27	26.9 $\pm$ 1.9	+0.37 $\pm$ 0.25
All three groups	300	150	85	65	27.76 $\pm$ 1.5	+0.50 $\pm$ 0.25

GA, gestational age; RE, refractive error.



**Figure 1.** Lower Foveal Thickness of Both Eyes in One of Children With History of ROP and Bevacizumab Injection.

This cross-sectional study was carried out in 2021-2022 to examine the preterm children aged 4-6 who had visited the ROP clinic of Nikookari hospital in Tabriz, Iran between 2015-2017 for the diagnosis and treatment of ROP. According to the study results, 79% of the eyes receiving bevacizumab had stage III ROP and 26% of them had stage I. As for children with spontaneously improved ROP, however, only 6% of them had Stage III ROP and 61% of them had stage I. The observed difference was significant, and may have justified the application of bevacizumab by the patients. It was found that 21% and 70% of children in the group receiving bevacizumab had ROP involvement in Zone I and Zone II, respectively; however, no cases of Zone I involvement, 45% of Zone II and 55% had Zone III involvement were observed in the group with spontaneous improvement of ROP.

**Foveal Thickness in ROP Children**

Our study results revealed that the average thickness of the central 0.5 mm of the macula (fovea) was  $235.46 \pm 11 \mu\text{m}$  in the group receiving bevacizumab,  $267.70 \pm 12 \mu\text{m}$  in the group with spontaneous improvement of ROP, and  $269.48 \pm 10 \mu\text{m}$  in the group with no ROP. According to these findings, the mean thickness of the fovea in the group receiving bevacizumab was significantly lesser than those of other two groups, which was suggestive of the negative effects of bevacizumab on the normal macular development in these infants.

Among factors affecting foveal thickness, macular edema has been reported in approximately 50% of sever ROP cases (13,14), and it has been detected that the prevalence of edema increases with an increase in ROP stage (13). It has been also demonstrated that in infants with macular edema, the fovea and inner nuclear layer thicknesses increase with edema severity, and that

variations in layer thicknesses in infants at  $36 \pm 1$  weeks' postmenstrual age may reflect abnormalities resulting from delay in foveal development possibly impacted by macular edema, ROP, or both (14). In our study, time point of visit was different (children at age 4 to 6 years) and in these children no macular edema was detected due to the period of time passed.

In a study by Lepore et al, all bevacizumab-treated eyes of children aged four years showed abnormalities at periphery (i.e., avascular area, vessel leakage, shunts, abnormal vessel branching, and tangles) or posterior pole (i.e., hyperfluorescent lesions and absence of FAZ). These lesions were not observed in majority of the lasered eyes (15). The authors, however, did not investigate foveal thickness in their study.

Vinekar et al investigated macular changes in acute ROP in infants. Despite clinically normal fovea (29.1%) with stage 2 ROP showed abnormal foveal changes. The mean central foveal thickness was  $206.5 \pm 98.7$  for stage 2. They identified two patterns of foveal involvement: "pattern A", which was characterized by dome-shaped foveal elevation and cystoid spaces with highly reflective intervening vertical septae; and "pattern B", which was characterized by preservation of the foveal depression with fewer intraretinal cystoid spaces. At 52 weeks' postmenstrual age all of them revealed normalization of foveal contours. They suggested that transient foveal changes at the critical time of fovealization in premature infancy may have influenced visual acuity in the adulthood (16). Since they investigated macular changes in acute ROP, the increased foveal thicknesses were likely.

In a study by Villegas et al, children treated with laser had lesser foveal thicknesses and lower visual acuity in comparison with spontaneously improved group, which may have been due to more advanced stages of ROP in the laser-treated eyes. They also reported that 64% had good visual acuity despite an abnormal foveal depression in 91% of total eyes, implying that an absent foveal pit and retention of the inner retinal layers did not preclude the development of good visual acuity. They suggested that foveal photoreceptor maturation may have occurred despite an abnormal foveal depression, which may have explained the preserved visual function in many of these patients (17)

Hammer et al explored OCT on older individuals with historically mild ROP, and detected neurovascular abnormalities in 77.8% of the patients. Years after suffering

**Table 3.** RNFL Thickness of the Quadrants in Micrometers

ROP	Average RNFL Thickness			
	Temporal	Nasal	Inferior	Superior
No ROP	72.80±10	76.13±10	129.91±10	138.90±10
Spontaneous improving	69.20±10	65.22±10	119.62±10	129.45±10
Bevacizumab	60.12±10	63.13±10	101.52±10	107.43±10
All groups	67.37±10	68.16±10	117.01±10	125.26±10

from mild ROP, their patients presented with degraded best corrected acuity attributed to mild optical aberration or metabolic effects on neural cells that are sensitive to contrast. They also argued that the loss of foveal cones or increased cone–cone spacing was responsible for these changes, and that there was not lack of cones years later (18). The transient edema may contribute to abnormalities in cone packing without affecting the actual number of cones by causing increased physical separation between adjacent cones that may inhibit their tight packing during the immaturity period (16,18).

Studies have demonstrated that children with regressed ROP have dysplasia of the central foveal structure, including a shallow or absent foveal pit, a thicker outer nuclear layer, and an inner retinal layer overlaying the fovea shown by OCT. Studies have also indicated that the foveal microvasculature may play a role in foveal pit formation, and that the mechanical stress or the ingrowing vessels may result in the failure in foveal pit formation (19,20).

The study by Vogel et al found that intravitreal bevacizumab therapy for ROP was associated with more rapid outer retinal thickening at the foveal center, whereas laser photocoagulation (LPC) was associated with earlier extrusion of the inner retinal layers and delayed development of the ellipsoid zone at the foveal center (21).

In a study by Kizilay and Akarsu Acar, central foveal thickness (CFT) was significantly higher in infants who had received treatment for ROP. Parafoveal and perifoveal retinal thicknesses in certain quadrants were higher in those receiving LPC treatment than in others. CFT was significantly lesser in group spontaneously improved compared to that in both groups, bevacizumab, and laser ( $P < 0.001$ ). The parafoveal average, temporal, inferior, and nasal thickness values as well as the perifoveal average, superior, and temporal thickness results were significantly higher in laser group than those in both other groups (22). In fact, it is inevitable to have higher thickness in laser group; in contrast to our study, however, CFT was lower in spontaneously improved group than that in the bevacizumab group.

### RNFL Thickness in ROP Children

This study indicated a significant difference between the group receiving bevacizumab and other two groups in terms of the thickness of RNFL, so that the thickness of the nerve layer of the retina in the group receiving bevacizumab was less than that in other two groups. In a study by Park and Oh, global average, nasal, and superior disc RNFL thickness profiles were significantly smaller in preterm children compared with full-term children (23). It is not known if ROP affects RNFL thickness directly, or the development of ROP and laser treatment for ROP can induce more RNFL thinning (24). Since RNFL thickness around the optic nerve is argued to decrease with diabetic retinopathy, it is suggested that severe ROP

could damage the axons of ganglion cells in a similar fashion (25), which may have also explained the reason of RNFL thickness decrease in this study. Furthermore, Kopic et al investigated the RNFL thickness in glaucoma patients treated with multiple intravitreal bevacizumab injections. It is known that the patients with primary open angle glaucoma (POAG) also have RNFL thinning. However, it is not known if administering bevacizumab to patients with POAG leads to additional reduction of RNFL thickness which their study results showed a decrease of RNFL thickness in both groups of patients (26), so RNFL thinning could be due to ROP and its effects, atrophy and bevacizumab injection too.

According to our study findings, moreover, the thickness of the RNFL in the temporal quadrant was lesser than that in other quadrants and close to the nasal quadrant, but it was higher in the superior quadrant than that in the other quadrants. In a study by Hammer et al, the thickness of inner retinal layers in subjects with ROP was slightly greater nasally than temporally (18). In a study by Fieß et al Patients with severe ROP had a thicker RNFL in the temporal sector compared with normal full-term controls (27). Another explanation for the decreasing thickness of the RNFL in the quadrants except for the temporal is occurrence of possible artifacts from the vessels. Children with low birth weight have narrower arterioles, and arteriolar caliber is positively correlated with RNFL thickness and macular thickness. Therefore, narrower vessels in preterm children compared with normal full-term controls could induce thinned RNFL measured by OCT (27, 28). Some studies have confirmed the association between peripapillary RNFL distribution and the presence of severe intraventricular hemorrhage (27). Wang et al reported that peripapillary RNFL thickness in the temporal side of the disc was related to visual acuity. Peripapillary RNFL is closely correlated with multiple visual deficits including visual field defect and low-contrast sensitivity (28).

The main strength of our study lies in the fact that it examined the macular and RNFL thickness in bevacizumab-treated eyes with history of ROP, which was not directly measured in previous studies. In our study, it was also argued that bevacizumab had the potential to negatively affect the normal macular development; however, uncertainty remained as to whether these macular changes were caused by bevacizumab alone or were produced due to the lower gestational age of the subjects treated with bevacizumab, which can affect the macular structure profoundly. Our study findings also facilitated understanding the development of premature fovea, which may have cleared the way for identifying the possible clinical and long-term effects of these abnormal changes on adulthood visual acuity.

This study faced few limitations. First, axial length and its adjustment to visual acuity of the participants as well as the children unwilling to cooperate on visual acuity exams

were not investigated in this study. Second, laser-treated eyes should be favorably studied as a separate group, which was not possible in our study due to inadequate laser-treated eyes.

Therefore, it was recommended that the laser-treated eyes should be investigated separately in order to extend our understanding of the development of premature fovea and other aspects of ROP as well as to prevent blindness caused by this condition.

#### Authors' Contribution

**Conceptualization:** Bahareh Javani, Amir Eftekhari Milani.

**Data curation:** Bahareh Javani, Amir Eftekhari Milani, Mehdi Abdi Shahshahani, Mohamd Hosein Ahoor, and Fereshteh Farhadi.

**Formal Analysis:** Bahareh Javani, Mehdi Abdi Shahshahani, Fereshteh Farhadi.

**Funding acquisition:** Amir Eftekhari Milani.

**Investigation:** Bahareh Javani, Mehdi Abdi Shahshahani, Amir Eftekhari Milani.

**Methodology:** Bahareh Javani, Mehdi Abdi Shahshahani, Amir Eftekhari Milani.

**Project administration:** Amir Eftekhari Milani.

**Resources:** Amir Eftekhari Milani, Mohamd Hosein Ahoor.

**Supervision:** Amir Eftekhari Milani.

**Validation:** Fereshteh Farhadi, Amir Eftekhari Milani.

**Visualization:** Fereshteh Farhadi, Amir Eftekhari Milani, Bahareh Javani.

**Writing—original draft:** Fereshteh Farhadi.

**Writing—review & editing:** Fereshteh Farhadi, Bahareh Javani, Amir Eftekhari Milani, Mehdi Abdi Shahshahani, Mohamd Hosein Ahoor.

#### Conflict of Interests

The authors declare that they have no relevant financial or non-financial interests to disclose.

#### Ethical Issues

This study was approved by the institutional review board of Tabriz University of Medical Sciences under approval ID of "IR.TBZMED.REC.1400.049", and was performed in accordance with the Declaration of Helsinki. Informed consent was obtained from the parents or legal guardians of all the children imaged.

#### Financial Support

This study was supported by Nikookari Hospital and Tabriz University of medical sciences. The authors declare that they received no grants or other support during the preparation of this manuscript.

#### References

- Loganathan PK, Nair V, Lal MK. Retinopathy of prematurity: overview of new global problem. *Paediatr Child Health*. 2022;32(9):311-323. doi:10.1016/j.paed.2022.07.001
- Hartnett ME, Penn JS. Mechanisms and management of retinopathy of prematurity. *N Engl J Med*. 2012;367(26):2515-2526. doi:10.1056/NEJMra1208129
- Gilbert C, Rahi J, Eckstein M, O'Sullivan J, Foster A. Retinopathy of prematurity in middle-income countries. *Lancet*. 1997;350(9070):12-14. doi:10.1016/s0140-6736(97)01107-0
- Quinn GE, Ying GS, Bell EF, et al. Incidence and early course of retinopathy of prematurity: secondary analysis of the postnatal growth and retinopathy of prematurity (G-ROP) study. *JAMA Ophthalmol*. 2018;136(12):1383-1389. doi:10.1001/jamaophthalmol.2018.4290
- Good WV, Hardy RJ, Dobson V, et al. The incidence and course of retinopathy of prematurity: findings from the early treatment for retinopathy of prematurity study. *Pediatrics*. 2005;116(1):15-23. doi:10.1542/peds.2004-1413
- Mintz-Hittner HA, Kennedy KA, Chuang AZ. Efficacy of intravitreal bevacizumab for stage 3+ retinopathy of prematurity. *N Engl J Med*. 2011;364(7):603-615. doi:10.1056/NEJMoa1007374
- Kang HG, Choi EY, Byeon SH, et al. Anti-vascular endothelial growth factor treatment of retinopathy of prematurity: efficacy, safety, and anatomical outcomes. *Korean J Ophthalmol*. 2018;32(6):451-458. doi:10.3341/kjo.2018.0011
- Fukushima Y, Fujino T, Kusaka S, Hatsukawa Y, Nishida K. Favorable outcomes of adequate laser photocoagulation and salvage bevacizumab treatment for aggressive posterior retinopathy of prematurity. *Am J Ophthalmol Case Rep*. 2018;11:66-71. doi:10.1016/j.ajoc.2018.05.006
- Eftekhari Milani A, Hassanpoor N, Mousavi Mirkala M, Taheri A, Golizade A, Niyousha MR. Intravitreal bevacizumab injection in aggressive posterior retinopathy of prematurity compared with type I retinopathy of prematurity. *Int Ophthalmol*. 2020;40(2):477-482. doi:10.1007/s10792-019-01208-3
- Patel NA, Acaba-Berroc LA, Hoyek S, et al. Practice patterns and outcomes of intravitreal anti-VEGF injection for retinopathy of prematurity: an international multicenter study. *Ophthalmology*. 2022;129(12):1380-1388. doi:10.1016/j.ophtha.2022.07.009
- Tsiropoulos GN, Seliniotaki AK, Haidich AB, Ziakas N, Mataftsi A. Comparison of adverse events between intravitreal anti-VEGF and laser photocoagulation for treatment-requiring retinopathy of prematurity: a systematic review. *Int Ophthalmol*. 2022. doi:10.1007/s10792-022-02480-6
- Miki A, Yamada Y, Nakamura M. The size of the foveal avascular zone is associated with foveal thickness and structure in premature children. *J Ophthalmol*. 2019;2019:8340729. doi:10.1155/2019/8340729
- Erol MK, Ozdemir O, Turgut Coban D, et al. Macular findings obtained by spectral domain optical coherence tomography in retinopathy of prematurity. *J Ophthalmol*. 2014;2014:468653. doi:10.1155/2014/468653
- Mangalesh S, McGeehan B, Tai V, et al. Macular OCT characteristics at 36 weeks' postmenstrual age in infants examined for retinopathy of prematurity. *Ophthalmol Retina*. 2021;5(6):580-592. doi:10.1016/j.oret.2020.09.004
- Lepore D, Quinn GE, Molle F, et al. Follow-up to age 4 years of treatment of type 1 retinopathy of prematurity intravitreal bevacizumab injection versus laser: fluorescein angiographic findings. *Ophthalmology*. 2018;125(2):218-226. doi:10.1016/j.ophtha.2017.08.005
- Vinekar A, Avadhani K, Sivakumar M, et al. Understanding clinically undetected macular changes in early retinopathy of prematurity on spectral domain optical coherence tomography. *Invest Ophthalmol Vis Sci*. 2011;52(8):5183-5188. doi:10.1167/iovs.10-7155
- Villegas VM, Capó H, Cavuoto K, McKeown CA, Berroc AM. Foveal structure-function correlation in children with history of retinopathy of prematurity. *Am J Ophthalmol*. 2014;158(3):508-512.e502. doi:10.1016/j.ajo.2014.05.017
- Hammer DX, Iftimia NV, Ferguson RD, et al. Foveal fine structure in retinopathy of prematurity: an adaptive optics Fourier domain optical coherence tomography study. *Invest Ophthalmol Vis Sci*. 2008;49(5):2061-2070. doi:10.1167/iovs.07-1228
- Yanni SE, Wang J, Chan M, et al. Foveal avascular zone and foveal pit formation after preterm birth. *Br J Ophthalmol*. 2012;96(7):961-966. doi:10.1136/bjophthalmol-2012-301612
- Chen YC, Chen YT, Chen SN. Foveal microvascular anomalies on optical coherence tomography angiography and the correlation with foveal thickness and visual acuity in retinopathy of prematurity. *Graefes Arch Clin Exp Ophthalmol*. 2019;257(1):23-30. doi:10.1007/s00417-018-4162-y
- Vogel RN, Strampe M, Fagbemi OE, et al. Foveal development in infants treated with bevacizumab or laser photocoagulation for retinopathy of prematurity. *Ophthalmology*. 2018;125(3):444-452.

- doi:10.1016/j.ophtha.2017.09.020
22. Kizilay O, Akarsu Acar OP. Swept-source optical coherence tomography in preschool children with a history of treated or spontaneously regressed retinopathy of prematurity. *Semin Ophthalmol.* 2022;37(6):780-785. doi:10.1080/08820538.2022.2100713
  23. Park KA, Oh SY. Retinal nerve fiber layer thickness in prematurity is correlated with stage of retinopathy of prematurity. *Eye (Lond).* 2015;29(12):1594-1602. doi:10.1038/eye.2015.166
  24. Åkerblom H, Holmström G, Eriksson U, Larsson E. Retinal nerve fibre layer thickness in school-aged prematurely-born children compared to children born at term. *Br J Ophthalmol.* 2012;96(7):956-960. doi:10.1136/bjophthalmol-2011-301010
  25. Muqit MM, Wakely L, Stanga PE, Henson DB, Ghanchi FD. Effects of conventional argon panretinal laser photocoagulation on retinal nerve fibre layer and driving visual fields in diabetic retinopathy. *Eye (Lond).* 2010;24(7):1136-1142. doi:10.1038/eye.2009.308
  26. Kopic A, Biuk D, Barac J, Vinkovic M, Benašić T, Kopic V. Retinal nerve fiber layer thickness in glaucoma patients treated with multiple intravitreal anti-VEGF (bevacizumab) injections. *Acta Clin Croat.* 2017;56(3):406-414. doi:10.20471/acc.2017.56.03.07
  27. Fieß A, Schäffler A, Mildenerger E, et al. Peripapillary retinal nerve fiber layer thickness in adults born extremely, very, and moderately preterm with and without retinopathy of prematurity: results from the Gutenberg Prematurity Eye Study (GPES). *Am J Ophthalmol.* 2022;244:88-97. doi:10.1016/j.ajo.2022.07.019
  28. Wang J, Spencer R, Leffler JN, Birch EE. Characteristics of peripapillary retinal nerve fiber layer in preterm children. *Am J Ophthalmol.* 2012;153(5):850-855.e1. doi:10.1016/j.ajo.2011.10.028

**Copyright** © 2023 The Author(s); This is an open-access article distributed under the terms of the Creative Commons Attribution License (<http://creativecommons.org/licenses/by/4.0>), which permits unrestricted use, distribution, and reproduction in any medium, provided the original work is properly cited.