



Favorable Outcome of Disseminated Intravascular Coagulation in a Pregnant Woman due to Tuberculosis: A Case Report

Parisa Dini¹, Soheila Aminimoghaddam¹, Setare Nassiri^{1*}, Vahid Kaveh¹, Solmaz Sadeghi¹, Saeedeh Moslemi¹

Abstract

Introduction: Tuberculosis is relatively common in reproductive age and thereby can be observed in pregnancy. Some of the clinical presentations of tuberculosis overlap with nonspecific symptoms that are found in normal pregnancy. Therefore, delay in diagnosis is understandable. The aim of our study is to indicate that tuberculosis is related to sanitary inadequacy and crowding and should be considered in every patient with such circumstances.

Case Presentation: This case report is about a pregnant woman who referred to us with low-grade fever and ascites and then disseminated intravascular coagulation was observable. Accordingly, several differential diagnoses were considered, and eventually, visceral tuberculosis was detectable.

Conclusions: It is recommended that tuberculosis be considered in every patient even without any response to the usual treatments. Extrapulmonary tuberculosis, which is more common in pregnancy, poses a tremendous challenge on the diagnosis and treatment of tuberculosis.

Keywords: Pregnancy, Tuberculosis, Disseminated intravascular coagulation

Introduction

The incidence of tuberculosis was about 9 million new cases in 2009 (1). Tuberculosis continues to kill about 2 million people per year in the world. The latent disease will eventually change into tuberculosis in 5%-10% of patients (2). About 1.75 billion people are infected with mycobacterium tuberculosis worldwide (3). Given that more than 75% of patients are at the age of 15-54 years, this is considered as a perceived threat, especially in pregnant women and is needed to keep in mind (4). Based on recent evidence, the incidence of tuberculosis is estimated at about 4.2 per 100 000 maternities and it is a major cause of maternal mortality (5). As a matter of fact, two vital issues should be addressed in a pregnant woman with tuberculosis, including the effect of disease on the mother and her fetus, as well as the impact of pregnancy on the usual clinical presentations of the disease. Some studies appear to show neither negative nor positive effects by means of tuberculosis in pregnancy (6,7). However, due to nonspecific symptoms contributed to a normal pregnancy, a delay in diagnosis occurs in many patients. Obstetric complications include abortion, preterm labor, fetal growth restriction, and transmission to the fetus. The increasing rate of complication is associated with the severity of the disease, extrapulmonary involvement, and co-infection with human immunodeficiency virus

(8,9). Disseminated intravascular coagulation is detected in tuberculosis and reported in a few articles (10-12). To the best of our best knowledge, this is the first case presentation of extrapulmonary tuberculosis in pregnancy which leads to disseminated intravascular coagulation. The aim of our study was to keep in mind that tuberculosis is related to sanitary inadequacy and crowding and, tuberculosis should be considered in every patient with such circumstances.

Case Presentation

A 24-year-old pregnant woman G3P2L2 referred to our tertiary center, namely, Firoozgar hospital, Tehran, Iran, with fever and inadequate weight gain at 32 weeks of the gestational age. On administration, she seemed ill. Vital signs were at a normal range although the temperature was 38, 2 degrees of Celsius orally. Based on the examination, the heart and lung had no remarkable sign while the abdomen was distant and tense without tenderness. Abdominal sonography demonstrated moderate to severe ascites in abdominopelvic cavity, normal liver, and biliary duct, and normal kidneys. Fetal biometry, amniotic fluid volume, and placenta were normal. The paracentesis of ascites was associated with an exudative pattern. Chest radiography (CXR) had a nonspecific pattern. Thus, spiral computerized tomography (CT) was performed and mild



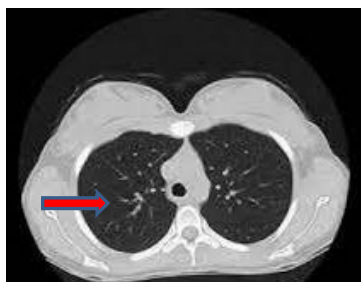

Figure 1. Spiral Computerized Tomography. Note. Spiral computerized tomography was performed and mild plural effusion addition to bronchiole wall thickening was detected.

pleural effusion addition to bronchiole wall thickening was detected as well (Figure 1). Laboratory data are provided in Table 1.

According to anorexia, upper gastrointestinal endoscopy was done and no ulcer or malignancy was observed. The tuberculin skin test, sputum test, and traditional culture were considered for the woman because she was an immigrant. The results of the above-mentioned tests were negative for tuberculosis. In the first place, bronchopneumonia was diagnosed and ceftriaxone plus azithromycin were prescribed accordingly. After 5 days of hospitalization, thrombocytopenia appeared and the platelet count dropped to 68000. In spite of normal blood pressure and the lack of severe signs, preeclampsia and HELLP syndrome were ruled out by means of laboratory tests. The hematology consult was performed and coagulation tests was requested (prothrombin time: 17 seconds, Partial thromboplastin time: 56). She received two units of fresh frozen plasma (FFP). One day later, the urine was hematuria and the platelet count dropped to 52000. Based on our joint committee, the termination of pregnancy was the sole option. Therefore, a cesarean section was done due to breech presentation via a vertical incision. The fetus was stable and 1550 in weight. Abdomen

Table 1. The Laboratory Date of the Patient

| | |
|-------------------------|------------|
| Hemoglobin level | 9.5 g/dL |
| White blood cell count | 4400/cc |
| Platelet | 268 000/cc |
| Serum albumin | 3.2 g/dL |
| Creatinine | 0.6 mg/dL |
| TSH | 1.8 Mu/L |
| ANA | Negative |
| Anti-ds DNA | Negative |
| Anti-cardiolipin | Negative |
| Stool exam occult blood | 0-1 |
| Stool culture | Negative |
| Urine RBC | 1-2 |
| Urine culture | Negative |
| Total bilirubin | 1.1 mg/dL |
| Alkaline phosphatase | 320 IU/L |

Note. TSH: Thyroid-stimulating hormone; ANA: Anti-nuclear antibody; RBC: Red blood cell count.

cavity was explored. There were multiple granulomas on the peritoneal and uterine surface in addition to omental thickening (Figure 2). The frozen section examination was performed and granuloma was determined accordingly. She received 2 units of packed cells, 4 units of platelets, and 2 units of FFP. According to permanent pathology results prepared for 48 hours and revealed tuberculosis, the anti-tuberculosis drug was started for her. On histopathological examinations, omentum and uterine serous were involved by necrotizing granulomatous (Figure 3) and a dramatic response amid 24 hours was observed and after 7 days, the patient was discharged with anti-tuberculosis drugs for 9 months. The neonatal specialist prevented breastfeeding and fortunately, congenital tuberculosis was ruled out after complete assessments. Now, after 9 months, she and her son are free of any symptoms.

Discussion

Tuberculosis is associated with human crowding and socioeconomically inadequacy. In addition, Tuberculosis may infect pregnant women, and evidence suggests that with luck this occasion can be diagnosed in the first place. A delay in diagnosis is more common, especially in a pregnant woman. The clinical symptoms of the disease are masked in pregnancy. Nevertheless, there are measures which can catch it up. The tuberculin skin test should be performed and pregnancy does not affect the result. Conventional culture for tuberculosis is also used in pregnancy although it takes 4-6 weeks to achieve a result (13). Based on the World Health Organization, symptoms such as chronic cough with any duration, night

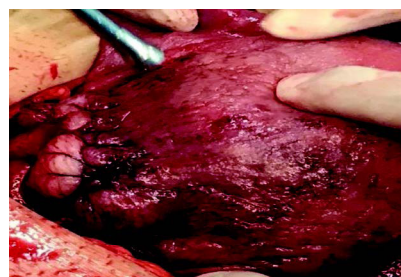


Figure 2. Uterus With the Patchy Granulation Tissue on it due to Tuberculosis

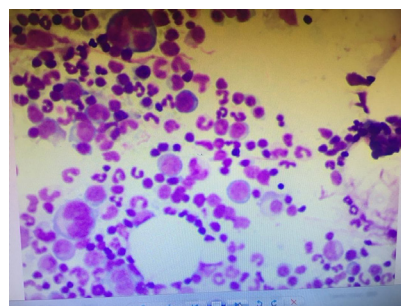


Figure 3. Microscopic View of the Omentum Specimen Showing Granulation and Diffuse Lymphocytosis, revealed as Tuberculosis

sweat, chronic fever, and weight loss screening should be considered in symptomatic women. Nonetheless, the Center for Disease Control and Prevention recommended a CXR for symptomatic and asymptomatic women who have had a recent tuberculosis contact (14,15). Given that military tuberculosis and extrapulmonary tuberculosis are more common in pregnancy, CXR and sputum examination may miss the diagnosis. Accordingly, it was understandable why we did not diagnose tuberculosis until surgery. However, we considered differential diagnoses including preeclampsia, HELLP syndrome, and collagen vascular disease which all were more popular in the patient. There is little difference in the management of tuberculosis in pregnancy. A combination of isoniazid, rifampin, ethambutol, and pyridoxine is prescribed for active tuberculosis in pregnancy and postpartum (16). Pyridoxine should be taken to decrease the peripheral neuropathy of the isoniazid (isonicotinic acid hydrazide) in pregnancy. For extrapulmonary disease, the same drugs with similar doses are recommended for 9-12 months (17). In congenital tuberculosis, the lung is the second organ which is involved while pre-portal lymph nodes near the liver are infected in the first place. More precisely, the haematogenous spread is the most important way that leads to congenital disease (18). Breastfeeding poses a tremendous challenge and based on the American Academics of Pediatrics, patients who are treated extravagantly amid two or more weeks before delivery can feed their newborn (19).

For our patient, breastfeeding was prevented and isoniazid was started for neonates until ruling out congenital tuberculosis. Considering a dramatic decrease in tuberculosis burden over the past several years, the lack of attention was understandable. However, in high-risk regions such as our country, we should embrace that it can seriously jeopardize the prognosis of the disease in patients because we usually forget it. Critical doubts must be addressed in the first place when ruling out ordinary differential diagnosis. Tuberculosis can lead to glaring disparities in clinical presentation and has a wide spectrum of symptoms and signs. Compared to other reports, disseminated intravascular coagulation is highly rare in tuberculosis and is reported in few studies (17-19). To the best of our best knowledge, as mentioned above, this is the first case report of extra pulmonary tuberculosis in pregnancy which leads to disseminated intravascular coagulation. Finally, as the most significant clinical usage of our report, given that the overwhelming majority of patients are attributed to the reactivation of latent disease, we recommend the screening test in people at the highest risk such as the immigrant population to identify latent disease, and subsequently, start a drug with less adverse effects. Anti-tuberculosis drugs in asymptomatic pregnant women may pose a threat although public health takes priority and it seems strategically wise. A large part of the problem lies with the shortage of outreach and the

resource for screening latent tuberculosis. However, if we want to succeed, we should figure out the cost and pay it. Therefore, future studies should be done to declare the cost and benefit of screening.

Authors' Contribution

PD gathered the data. SA collected the laboratory data. SN drafted the manuscript. VK designed the article. SM and SS designed the photos. All authors have confirmed the final article.

Conflict of Interests

Authors declare that they have no conflict of interests.

Ethical Issues

Informed consent was taken from the patient.

Financial Support

The present study received no financial support.

References

1. World Health Organization (WHO). Global Tuberculosis Report 2013. WHO; 2013.
2. Mathad JS, Gupta A. Tuberculosis in pregnant and postpartum women: epidemiology, management, and research gaps. *Clin Infect Dis*. 2012;55(11):1532-1549. doi:10.1093/cid/cis732
3. Global tuberculosis control: key findings from the December 2009 WHO report. *Wkly Epidemiol Rec*. 2010;85(9):69-80.
4. World Health Organization (WHO). Global Tuberculosis Control 2010. Geneva: WHO; 2012.
5. Knight M, Kurinczuk JJ, Nelson-Piercy C, Spark P, Brocklehurst P. Tuberculosis in pregnancy in the UK. *BJOG*. 2009;116(4):584-588. doi:10.1111/j.1471-0528.2008.02097.x
6. Schaefer G, Zervoudakis IA, Fuchs FF, David S. Pregnancy and pulmonary tuberculosis. *Obstet Gynecol*. 1975;46(6):706-715.
7. Hedvall E. Pregnancy and tuberculosis. *Acta Med Scand Suppl*. 1953;286:1-101.
8. Jimenez-Arellanes A, Meckes M, Ramirez R, Torres J, Luna-Herrera J. Activity against multidrug-resistant *Mycobacterium tuberculosis* in Mexican plants used to treat respiratory diseases. *Phytother Res*. 2003;17:903-908. doi:10.1002/ptr.1377
9. Pillay T, Khan M, Moodley J, Adhikari M, Coovadia H. Perinatal tuberculosis and HIV-1: considerations for resource-limited settings. *Lancet Infect Dis*. 2004;4(3):155-165. doi:10.1016/s1473-3099(04)00939-9
10. Tsubosaka S, Sasaki F, Ameshima S, et al. [A case of pulmonary tuberculosis associated with severe respiratory failure, DIC and intractable bilateral pneumothoraces]. *Kekkaku*. 1992;67(11):721-728.
11. Ishibatake H, Onizuka R. [A successfully treated case of miliary tuberculosis with adult respiratory distress syndrome and tuberculous aneurysm of abdominal aorta]. *Kekkaku*. 1998;73(6):403-411.
12. Shiraiishi S, Futami S, Kurahara Y, Tsuyuguchi K, Hayashi S, Suzuki K. [A case of miliary tuberculosis complicated by disseminated intravascular coagulation and acute respiratory distress syndrome successfully treated with recombinant human soluble thrombomodulin]. *Kekkaku*. 2012;87(12):771-776.
13. Loto OM, Awowole I. Tuberculosis in pregnancy: a review. *J Pregnancy*. 2012;2012:379271. doi:10.1155/2012/379271
14. American Thoracic Society, CDC, and Infectious Diseases Society of America. Treatment of tuberculosis. *MMWR Recommendations and reports: Morbidity and mortality*

- weekly report Recommendations and reports. <https://www.cdc.gov/mmwr/pdf/rr/rr5211.pdf>
15. Good JT Jr, Iseman MD, Davidson PT, Lakshminarayan S, Sahn SA. Tuberculosis in association with pregnancy. *Am J Obstet Gynecol.* 1981;140(5):492-498. doi:10.1016/0002-9378(81)90222-2
 16. Sarner L, Fakoya A. Acute onset lactic acidosis and pancreatitis in the third trimester of pregnancy in HIV-1 positive women taking antiretroviral medication. *Sex Transm Infect.* 2002;78(1):58-59. doi:10.1136/sti.78.1.58
 17. Perucca E, Grimaldi R, Frigo GM, Sardi A, Mönig H, Ohnhaus EE. Comparative effects of rifabutin and rifampicin on hepatic microsomal enzyme activity in normal subjects. *Eur J Clin Pharmacol.* 1988;34(6):595-599. doi:10.1007/bf00615223
 18. Hamadeh MA, Glassroth J. Tuberculosis and pregnancy. *Chest.* 1992;101(4):1114-1120. doi:10.1378/chest.101.4.1114
 19. Khan M, Pillay T, Moodley JM, Connolly CA. Maternal mortality associated with tuberculosis-HIV-1 co-infection in Durban, South Africa. *Aids.* 2001;15(14):1857-1863. doi:10.1097/00002030-200109280-00016

© 2021 The Author(s); This is an open-access article distributed under the terms of the Creative Commons Attribution License (<http://creativecommons.org/licenses/by/4.0>), which permits unrestricted use, distribution, and reproduction in any medium, provided the original work is properly cited.