



# A Preliminary Study to Propose an Algorithm for Management of Cesarean Scar Pregnancy

Azam Tarafdari<sup>1</sup>, Sedigheh Borna<sup>1</sup>, Sheida Janastrostami<sup>1</sup>, Sedighe Hantoushzadeh<sup>1</sup>, Fatemeh Keikha<sup>1\*</sup>

## Abstract

**Objectives:** There is no consensus on the management of cesarean scar pregnancy (CSP). In this regard, this study proposed an algorithm for CSP management with consecutive outcomes.

**Materials and Methods:** In this randomized clinical trial study, the data of 44 patients with CSP were collected, and the diagnosis was confirmed by transvaginal ultrasonography (TVS). Unstable patients underwent uterine artery embolization (UAE), and the fetal reduction was done for patients with the fetal heart rate (FHR). In addition, patients received systemic methotrexate (MTX) injections according to their beta-human chorionic gonadotropin ( $\beta$ -hCG) levels and then were followed on a predetermined schedule by  $\beta$ -hCG levels and TVS. Finally, prophylactic UAE was considered for patients with ongoing bleeding, placental hypervascularity, and the prospect of limited access to care.

**Results:** Patients were within the age range of  $33.9 \pm 4.9$  years and the gestational age of  $7.37 \pm 1.57$  weeks. Twenty-two patients (50%) had vaginal bleeding, 3 of whom were unstable and underwent UAE. Five patients underwent a total abdominal hysterectomy, and fourteen patients with FHR underwent a fetal reduction. Based on  $\beta$ -hCG levels and changes, and placental vascularity, 4 patients received no treatment. In general, 11, 2, and 9 patients received single, double, and multiple MTX injections. A total of 10 patients underwent both multi-doses of MTX and prophylactic UAE. The median period to reach undetectable  $\beta$ -hCG levels was 7.3 weeks and the median interval to start menstruation was 2.8 weeks. In addition, the pregnancy remnant was resolved 3.6 months after the treatment. On the follow-up, no curettage or hysterectomy was needed and seven patients became pregnant (15.9%), 2 of whom presented recurrent CSP (28.6%).

**Conclusions:** The proposed stepwise algorithm could be employed for CSP management with accountable outcomes, low hysterectomy rates, and fertility preservation.

**Keywords:** Cesarean scar pregnancy, Embolization, Hysterectomy management, Systemic methotrexate

## Introduction

With the increasing utilization of cesarean section for delivery, there has been a recent rise in the identification of a particular type of ectopic pregnancies. In these ectopic pregnancies, namely, cesarean scar pregnancy (CSP), there is gestational sac implantation in the hysterotomy scar, which was first described by Larsen and Solomon in 1978 (1). It is assumed that endometrial and myometrial disruption due to poor healing can predispose abnormal pregnancy implantation in this area although it has been speculated that implantation may occur through a microscopic tract into the myometrium (2-4). CSP is a life-threatening condition that can cause abnormal placentation, uterine rupture, and hemorrhage and can even lead to death (5).

Different modalities have been suggested for CSP management, including systemic or local methotrexate (MTX) injection, uterine artery embolization (UAE), surgical wedge resection, and hysteroscopic management (6-8). Despite the rising incidence, current evidence is still based on case series and individual case reports,

and there is no consensus or established guideline on the management of CSP (9). In this report, we reviewed our experience in the management of CSP over the past 3 years in our referral center, suggesting a decision-making algorithm in this respect.

## Materials and Methods

Forty-four patients with CSP were registered in our department from March 2014 to February 2017. The patients were referred with the diagnosis of CSP or were diagnosed during our assessments. The diagnosis was confirmed using transvaginal ultrasonography (TVS) by a single operator, namely, an experienced perinatologist (i.e., SB). For the diagnosis of CSP, we employed the criteria described by Timor-Tritsch et al (10). The vascularity of the gestational sac was also assessed by Doppler ultrasonography. The patients with severe vaginal bleeding and tachycardia or low blood pressure were considered unstable (11) and underwent UAE. On the other hand, stable patients were classified into two subgroups with and without a fetal heart rate (FHR). The patients with the



## Key Messages

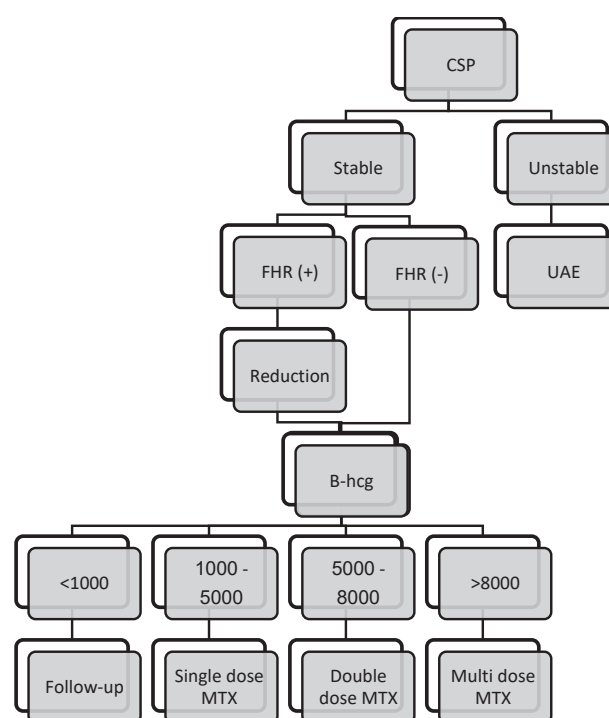
- Cesarean scar pregnancy (CSP) is a life-threatening condition that there is not any consensus about its management. The current study proposes an effective and minimally invasive algorithm for the management of CSP.

FHR underwent a fetal reduction by the injection of 2-3 mL potassium chloride (KCl) 15% under the sonographic guide. The fetal death was confirmed the next morning by TVS. These patients and those without the FHR from the beginning were treated with MTX according to their beta-human chorionic gonadotropin ( $\beta$ -hCG) level. However, patients were not injected by MTX if the  $\beta$ -hCG level was below 1000 (12). The  $\beta$ -hCG level was checked 48 hours later. If the  $\beta$ -hCG at 48 hours was in decrement, patients were followed by weekly determination of  $\beta$ -hCG levels until two  $\beta$ -hCG measurements became undetectable. Those without decreasing  $\beta$ -hCG were treated as patients in the next  $\beta$ -hCG level category. Those patients with  $\beta$ -hCG levels between 1000 and 5000 were hospitalized and injected with a single dose of 50 mg/m<sup>2</sup> MTX.  $\beta$ -hCG levels were measured at days 4 and 7 and followed weekly until two  $\beta$ -hCG measurements became undetectable. A second MTX injection was given to patients with less than a 15% reduction in  $\beta$ -hCG levels between days 4 and 7. After the second injection, patients were followed again by  $\beta$ -hCG at days 4 and 7 and then weekly. For patients with  $\beta$ -hCG between 5000 and 8000, a double-dose injection of 50 mg/m<sup>2</sup> MTX was done on the first and fourth days. Next,  $\beta$ -hCG was checked on days 7 and 11. A response to treatment was considered when at least a 15% reduction was achieved in  $\beta$ -hCG levels. Afterward,  $\beta$ -hCG monitoring was done weekly. Furthermore, a multi-dose regimen of MTX was administered in patients with initial  $\beta$ -hCG levels >8000. The multi-dose regimen was planned as the injections of 1 mg/kg at days 1, 3, 5, and 7 with additional intramuscular 0.1 mg/kg Folinic acid injections at days 2, 4, 6, and 8. The  $\beta$ -hCG was measured on days 1, 3, 5, and 7. The injection of MTX was discontinued whenever the  $\beta$ -hCG showed a >15% reduction. After the completion of chemotherapy, a TVS was performed to assess the vascularity of the gestational sac. Prophylactic UAE was proposed to patients with hypervascular gestational sacs and continuous vaginal bleeding after MTX injections or limited access to care secondary to living in remote regions. After two negative  $\beta$ -hCG measurements, another TVS was done for controlling and determining the remnants and the thickness of the scar-site myometrium. The patients with complete family planning or those representing no consent for UAE or MTX injections were suggested to undergo a hysterectomy. Patients rejected with prophylactic UAE were discharged and followed until reaching negative  $\beta$ -hCG levels. Moreover, they were followed for forthcoming pregnancies for at least 24

months (i.e., during the time of this report). The algorithm of the procedure is depicted in Figure 1. Written informed consent forms were collected from all participants, indicating that there was no standard of care for their condition, and all the adverse effects and consequences of the selection and decisions were discussed with patients.

## Results

Forty-four patients in the age range of  $33.9 \pm 4.9$  years with CSP were included in this study. The median cesarean section was one (interquartile range: 1-2) and median gravidity was 3 (interquartile range: 2-4). The median time interval after the previous cesarean was 5.1 years (interquartile range: 4-8). A history of myomectomy, curettage, and intervention for infertility was detected in 2 (4.5%), 16 (36.4%), and 2 (4.5%) patients, respectively. The mean gestational age was  $7.37 \pm 1.57$  weeks. In general, 22 patients (50%) had vaginal bleeding; 3 of whom were unstable. These 3 patients underwent UAE as the only treatment, one of them received a second UAE because of continuing bleeding. Five patients completed their family and decided to undergo a total abdominal hysterectomy. Among these patients, pathology examinations indicated 2 placenta accreta, 2 placenta increta, and 1 placenta percreta. In 14 patients with the detection of the FHR, the fetal reduction by the intracardiac injection of 2-3 mL KCl



**Figure 1.** Proposed Algorithm for the Management of CSP. Note. CSP: Cesarean section pregnancies; FHR: Fetal heart rate; UAE: Uterine artery embolization;  $\beta$ -hCG: Beta-human chorionic gonadotropin; MTX: Methotrexate. Unstable patients had vaginal bleeding with tachycardia or hypotension. The fetal reduction was done by sonographically guided KCl fetal injection for those with detectable (+) FHR; KCl: Potassium chloride.

15% was done under the guide of TVS employing mask general anesthesia. The procedure of the fetal reduction was successful in all patients but one who underwent a second injection. Based on  $\beta$ -hCG levels and changes, and placental vascularity, 4 patients received no treatment. Overall, 11 patients received a single MTX injection, 2 patients were treated with double injections, 9 patients underwent multiple injections, and 10 patients underwent both multi-doses of MTX injections and prophylactic UAE. A patient rejected with prophylactic UAE presented latterly with excessive bleeding and was treated by laparotomy.

The duration of hospitalization was insignificantly longer in those patients who received UAE after MTX injections ( $n=10$ , median 13 days, and interquartile 8-20 days) compare to patients treated with observation ( $n=4$ , Median 6 days, interquartile of 4-7 days,  $P=0.1$ ) and MTX injections ( $n=22$ , median 7.5 days, interquartile of 5-10 days,  $P=0.1$ , Table 1). The obtained data regarding remnant disappearance,  $\beta$ -hCG normalization, hospital stay duration, and menstrual cycle normalization are presented in Table 1.  $\beta$ -hCG levels become negative after 7.3 weeks, the median time for starting menstruation was 2.8 weeks, and the pregnancy remnant was resolved 3.6 months after the treatment.

Overall, 6 patients were transfused, 2 of whom were unstable at admission and received UAE initially. In addition, 2 cases underwent an abdominal hysterectomy, one case received UAE after MTX injections, and finally, one case received MTX injection as the only treatment. A patient receiving multi MTX doses experienced stomatitis and was treated conservatively. No metritis was detected in the patients of the current study. The follow-up curettage or hysterectomy was needed in none of the patients who received medical treatment by MTX injections. Additionally, hysteroscopy was done in a patient with continuous spotting and the placental polyp was detected and excised accordingly. A post embolization syndrome was detected and treated conservatively with a 2-day prolonged hospitalization. Asherman syndrome was consecutively developed in another patient who underwent UAE because of severe vaginal bleeding.

Seven patients became pregnant (15.9%); 2 presented recurrent CSP (28.6%) and were treated with hysterectomy

and cervical ripening balloon, respectively (not included in the current analysis). In addition, 3 cases had full-term uncomplicated delivery, one case was diagnosed to have placenta accreta at her 16 weeks of gestation planned to be terminated at 34 weeks, but finally, terminated at 37 weeks with cesarean hysterectomy (a live child, final diagnosis placenta percreta with bladder wall invasion), and finally, one intrauterine fetal death was detected and missed abortion at 12 weeks of gestation.

## Discussion

The rates of its adverse consequences, placenta accreta, and CSP have increased by the universal increasing rate of cesarean delivery (13). Despite this increase, there is no consensus about the best treatment and management approach. According to Timur-Tritsch et al (10), some interventions such as systemic MTX, dilatation and curettage, and UAE on their own, and not in combination with other methods, are not the treatment of choice for CSP. Systemic MTX as a single treatment for all CSP should be avoided mainly because of a long period before its effect, and particularly when FHR is detectable. A delay before a definite treatment may lead to the additional growth of the embryo/fetus and the vascularization of the sac.

In the current study, treatment choices were according to the patient's desire for future fertility, the presence of fetal heart activity, and hemodynamic stability. MTX as a single therapy was used when there was no fetal heart activity or as the second-line treatment after the fetal reduction with KCl injection. Regarding the systemic use of MTX for CSP, considering the low efficacy rate and high complications including fertility loss led to a new and possibly more effective approach with the local injection of MTX and the subsequent removal of the gestational tissue under the guide of hysteroscopy or ultrasonography (14). The current study did not use this method mainly because of the lack of experience and uncertainty about the dosage and follow-up schedules. It has been reported (15) that the mean time for  $\beta$ -hCG to become negative was significantly lower by local MTX injections (6.2 weeks) compared with the systemic MTX application (8.1 weeks). Our patients reached negative  $\beta$ -hCG levels in 7.3 weeks (the median time), which is less than the comparable systemic MTX

**Table 1.** Main End-points of the Caesarian Scare Pregnancy Treatment

	Observation n=4	MTX n=22	Single-dose MTX n=11	Double-dose MTX n=2	Multi-dose MTX n=9	UAE n=3	MTX plus UAE n=10
Time lapse to reach negative $\beta$ -hCG <sup>a</sup>	4.5 (4-13.2)	9 (5.5-10.7)	7 (4-9)	13 (13)	9.5 (9-15.5)	10 (7)	8.5 (6-10)
Time lapse to menstruation normalization	5 (2)	3 (2-6)	2 (2-5.5)	2 (2)	4 (3-7.5)	6 (6)	3.5 (2.75-6)
Time to remnant elimination <sup>b</sup>	2 (2)	3 (2-4)	3 (2-4)	3 (3)	3 (2.75-4.5)	5 (4)	4 (3-5)
Hospitalization period <sup>c</sup>	6 (4.5-6.75)	7.5 (5-10.2)	6 (4-8)	7 (6)	10 (7.5-18)	17 (12)	13 (8-20.5)

MTX: Methotrexate; UAE: Uterine artery embolization;  $\beta$ -hCG: Beta-human chorionic gonadotropin.

Note. Differences are significant for time lapse to  $\beta$ -hCG normalization (<sup>a</sup> $P=0.02$ ) between different MTX regimens, time to remnant eradication (<sup>b</sup> $P=0.02$ ) between different protocols, and hospitalization period (<sup>c</sup> $P=0.004$ ) between different protocols.

injection data obtained by Uludag et al (15) while similar to the results of Timor-Tritsch et al (16) demonstrating a median of 49 days before negative  $\beta$ -hCG.

UAE may obviate the need for laparotomy or laparoscopy to excise the trophoblastic tissue. The use of the UAE has its drawbacks. The success rate is low when the UAE is used as the single therapy (17) and future fertility might be hindered as well (18). Previously, UAE has been employed as a method for decreasing the risk of bleeding after the use of conservative management with MTX (19-22). We used UAE in unstable patients with severe vaginal bleeding or stable patients with continuous vaginal bleeding or the hyper-vascularization of the gestational sac or the evidence of AVM, particularly in those with limited future access to care (i.e., living in a remote area). The low transfusion rate and the lack of a need for emergency hysterectomy reflect the efficacy of the wise application of UAE in our approach. Yang et al (6) compared UAE with systemic MTX in 103 patients, in whom the regular menses was started after 3-10 months of treatment. The median time before regular menstruation was 2.8 months in the current study.

Dilatation and curettage, in the way that is used for missed or induced abortions, should be avoided because it can lead to profuse bleeding, which may lead to blood transfusion, needs general or spinal anesthesia, and additional downstream procedures including immediate UAE and laparotomy resulting in hysterectomy. Consequently and reasonably, in this study, dilatation and curettage was not considered as a treatment of choice and was not employed at all in the current patient series due to the effectiveness of the other applied methods. Recently, the hysteroscopic management of CSP has received attention even as the first line treatment (23). This method needs an experience to prevent unwanted complications including bladder injury. We may integrate it into our approach in the future.

Hysterectomy may be necessary for saving the patient's life when the excessive bleeding is not controllable by Tamponade-balloon, UAE, or the uterine artery ligation. In our patient series except those 5 patients who decided to undergo a hysterectomy, the use of our management algorithm provided excellent outcomes in terms of avoiding curettage, the low transfusion rate, and the high cure rate and forthcoming pregnancy. All the hysterectomies were done according to the patient's desire and decision and neither was done due to the failure of the treatment.

There are reports on successful term pregnancies after the CSP treatment (24,25), as well as maternal and fetal mortality and placenta accrete in subsequent pregnancies (26). Fortunately, we encountered no uterine rupture in subsequent pregnancies although many of our patients decided not to become pregnant anymore considering the subsequent pregnancy rate of about 16%. It has been recommended to do early ultrasonography in subsequent

pregnancy for the early detection of recurrent CSP (27). Based on the findings, 2 patients were observed with recurrent CSP (about 19%) in our series.

The proposed stepwise algorithm for the treatment of CSP in the current study was proved to be practical with acceptable outcomes. The low hysterectomy rate and the preservative use of MTX according to  $\beta$ -hCG levels could be achieved with the appropriate use of UAE/prophylactic UAE. Although there is no consensus on the treatment strategy for CSP, the current proposed approach could be put into practice then revised as a prototypic strategy in this regard.

#### Authors' Contribution

AT: Project development, data collection, and manuscript writing; SB: Project development and data collection; SJ: Data collection; SH: Project development and data collection; FK: Data collection and manuscript writing.

#### Conflict of Interests

Authors declare that they have no conflict of interests.

#### Ethical Issues

This study was approved by Tehran University of Medical Sciences as a residency thesis under number 96/21/10840 and was performed in accordance with the ethical standards laid down in the 1964 Declaration of Helsinki and all subsequent revisions. Informed consent was obtained from all participants.

#### Financial Support

None.

#### Acknowledgments

This study was designed and performed as a residency thesis and then supported by the Vali-asr Reproductive Health Research Center. The authors would like to thank the patients and the staff of the Infertility Department of Imam Khomeini Hospital Complex for all their help..

#### References

1. Larsen JV, Solomon MH. Pregnancy in a uterine scar sacculus—an unusual cause of postabortal haemorrhage. A case report. *S Afr Med J*. 1978;53(4):142-143.
2. Rotas MA, Haberman S, Levгур M. Cesarean scar ectopic pregnancies: etiology, diagnosis, and management. *Obstet Gynecol*. 2006;107(6):1373-1381. doi:10.1097/01.AOG.0000218690.24494.ce
3. Cömert EH, Şal H, Kizilet H, Ekici YS, Güvendağ Güven ES, Güven S. Cesarean scar pregnancy: a case report. *Türkiye Klinikleri J Case Rep*. 2018;26(1):37-39. doi:10.5336/gynobstet.2016-53978
4. Maymon R, Halperin R, Mendlovic S, et al. Ectopic pregnancies in caesarean section scars: the 8 year experience of one medical centre. *Hum Reprod*. 2004;19(2):278-284. doi:10.1093/humrep/deh060
5. Wang CB, Chiu WW, Lee CY, Sun YL, Lin YH, Tseng CJ. Cesarean scar defect: correlation between cesarean section number, defect size, clinical symptoms and uterine position. *Ultrasound Obstet Gynecol*. 2009;34(1):85-89. doi:10.1002/uog.6405
6. Yang H, Li S, Ma Z, Jia Y. Therapeutic effects of uterine artery embolisation (UAE) and methotrexate (MTX) conservative therapy used in treatment of cesarean scar pregnancy. *Arch Gynecol Obstet*. 2016;293(4):819-823. doi:10.1007/s00404-

- 015-3881-0
7. Peng P, Gui T, Liu X, Chen W, Liu Z. Comparative efficacy and safety of local and systemic methotrexate injection in cesarean scar pregnancy. *Ther Clin Risk Manag.* 2015;11:137-142. doi:10.2147/tcrm.s76050
  8. Dior UP, Palma-Dias R, Reidy KL, Cheng C, Healey M. Cesarean scar pregnancies: incidence and factors associated with conversion to surgery from medical management. *J Minim Invasive Gynecol.* 2019;26(5):919-927. doi:10.1016/j.jmig.2018.09.771
  9. Ambrósio B, Ferreira AP, Correia A. How to treat cesarean scar pregnancy: a difficult and rare case. *J Gynecol Surg.* 2018;34(2):99-101. doi:10.1089/gyn.2017.0081
  10. Timor-Tritsch IE, Monteagudo A, Santos R, Tsymbal T, Pineda G, Arslan AA. The diagnosis, treatment, and follow-up of cesarean scar pregnancy. *Am J Obstet Gynecol.* 2012;207(1):44.e41-13. doi:10.1016/j.ajog.2012.04.018
  11. Norwitz ER, Park JS. Overview of the Etiology and Evaluation of Vaginal Bleeding in Pregnant Women. Waltham: UpToDate; 2012.
  12. Nowak-Markwitz E, Michalak M, Olejnik M, Spaczynski M. Cutoff value of human chorionic gonadotropin in relation to the number of methotrexate cycles in the successful treatment of ectopic pregnancy. *Fertil Steril.* 2009;92(4):1203-1207. doi:10.1016/j.fertnstert.2008.07.1775
  13. Rafiei M, Saei Ghare M, Akbari M, et al. Prevalence, causes, and complications of cesarean delivery in Iran: a systematic review and meta-analysis. *Int J Reprod Biomed.* 2018;16(4):221-234.
  14. Pędraszewski P, Właźlak E, Panek W, Surkont G. Cesarean scar pregnancy - a new challenge for obstetricians. *J Ultrason.* 2018;18(72):56-62. doi:10.15557/JoU.2018.0009
  15. Uludag SZ, Kutuk MS, Ak M, et al. Comparison of systemic and local methotrexate treatments in cesarean scar pregnancies: time to change conventional treatment and follow-up protocols. *Eur J Obstet Gynecol Reprod Biol.* 2016;206:131-135. doi:10.1016/j.ejogrb.2016.09.010
  16. Timor-Tritsch IE, Monteagudo A, Bennett TA, Foley C, Ramos J, Kaelin Agten A. A new minimally invasive treatment for cesarean scar pregnancy and cervical pregnancy. *Am J Obstet Gynecol.* 2016;215(3):351.e1-8. doi:10.1016/j.ajog.2016.03.010
  17. He Y, Wu X, Zhu Q, et al. Combined laparoscopy and hysteroscopy vs. uterine curettage in the uterine artery embolization-based management of cesarean scar pregnancy: a retrospective cohort study. *BMC Womens Health.* 2014;14:116. doi:10.1186/1472-6874-14-116
  18. Krissi H, Hirsch L, Stolovitch N, Nitke S, Wiznitzer A, Peled Y. Outcome, complications and future fertility in women treated with uterine artery embolization and methotrexate for non-tubal ectopic pregnancy. *Eur J Obstet Gynecol Reprod Biol.* 2014;182:172-176. doi:10.1016/j.ejogrb.2014.09.026
  19. Yang MJ, Jeng MH. Combination of transarterial embolization of uterine arteries and conservative surgical treatment for pregnancy in a cesarean section scar. A report of 3 cases. *J Reprod Med.* 2003;48(3):213-216.
  20. Sugawara J, Senoo M, Chisaka H, Yaegashi N, Okamura K. Successful conservative treatment of a cesarean scar pregnancy with uterine artery embolization. *Tohoku J Exp Med.* 2005;206(3):261-265. doi:10.1620/tjem.206.261
  21. Chou MM, Hwang JI, Tseng JJ, Huang YF, Ho ES. Cesarean scar pregnancy: quantitative assessment of uterine neovascularization with 3-dimensional color power Doppler imaging and successful treatment with uterine artery embolization. *Am J Obstet Gynecol.* 2004;190(3):866-868. doi:10.1016/j.ajog.2003.11.030
  22. Ghezzi F, Laganà D, Franchi M, Fugazzola C, Bolis P. Conservative treatment by chemotherapy and uterine arteries embolization of a cesarean scar pregnancy. *Eur J Obstet Gynecol Reprod Biol.* 2002;103(1):88-91. doi:10.1016/s0301-2115(02)00003-9
  23. Deans R, Abbott J. Hysteroscopic management of cesarean scar ectopic pregnancy. *Fertil Steril.* 2010;93(6):1735-1740. doi:10.1016/j.fertnstert.2008.12.099
  24. Ben Nagi J, Helmy S, Ofili-Yebovi D, Yazbek J, Sawyer E, Jurkovic D. Reproductive outcomes of women with a previous history of caesarean scar ectopic pregnancies. *Hum Reprod.* 2007;22(7):2012-2015. doi:10.1093/humrep/dem078
  25. Vial Y, Petignat P, Hohlfeld P. Pregnancy in a cesarean scar. *Ultrasound Obstet Gynecol.* 2000;16(6):592-593. doi:10.1046/j.1469-0705.2000.00300-2.x
  26. Seow KM, Hwang JL, Tsai YL, Huang LW, Lin YH, Hsieh BC. Subsequent pregnancy outcome after conservative treatment of a previous cesarean scar pregnancy. *Acta Obstet Gynecol Scand.* 2004;83(12):1167-1172. doi:10.1111/j.0001-6349.2004.00445.x
  27. Rosen T. Placenta accreta and cesarean scar pregnancy: overlooked costs of the rising cesarean section rate. *Clin Perinatol.* 2008;35(3):519-529. doi:10.1016/j.clp.2008.07.003

© 2021 The Author(s); This is an open-access article distributed under the terms of the Creative Commons Attribution License (<http://creativecommons.org/licenses/by/4.0>), which permits unrestricted use, distribution, and reproduction in any medium, provided the original work is properly cited.