



## Maternal Health and Early outcome in Pregnant Woman with Eisenmenger syndrome and Ebstein Anomaly

Razieh Parizad <sup>1</sup>, Mehrnosh Toufan Tabrizi <sup>1\*</sup>, Maryam Chenaghloou <sup>1</sup>

### Article History:

Received September 2013

Accepted October 2013

Available online January 2014

### Keywords:

C/S (Cesarean Section)

CVA

Ebstein Anomaly

Eisenmenger

PCA (Posterior Cerebellar Artery)

Preeclamsia

Pregnancy Outcome

PSVT (Paroxysmal

Supraventricular Tachycardia)

### Corresponding Author:

Mehnosh Toufan Tabrizi ,  
Cardiovascular Research Center,  
Tabriz University of Medical  
Sciences, Tabriz, Iran

Tel: +989143111284

Email: mtoufan@gmail.com

### Abstract :

Eisenmenger syndrome (or ES, Eisenmenger reaction or tardive cyanosis) is defined as the process in which a left to right shunt caused by a congenital heart defect in the fetal heart causes increased flow through the pulmonary vasculature, causing pulmonary hypertension,(1) which in turn causes increased pressures in the right side of the heart and reversal of the shunt into a right-to-left shunt.

Eisenmenger syndrome is a cyanotic heart defect characterized by a long-standing intracardiac shunt (caused by "VSD": Ventricular septal defect, "PDA": Patent ductus arteriosus, or, less commonly, "ASD": Atrial septal defect ) that eventually reverses to a right-to-left shunt. This syndrome is less frequent today because of medical screening with echocardiography early in life. Eisenmenger syndrome specifically refers to the combination of a cardiac shunt (systemic-to-pulmonary), significant enough to cause cyanosis and overtime pulmonary hypertension.

Pregnancy should ideally be avoided in a woman with Eisenmenger syndrome, since it carries a high (approximately 50 percent) risk of sudden death for mother, frequently occurring a few days postpartum (2). However, a case of Eisenmenger syndrome and Ebstein anomaly in pregnancy where the patient's postpartum complications were successfully managed is reported..

1. Cardiovascular Research Center, Tabriz University of Medical Sciences, Tabriz, Iran.

### Introduction:

Pregnancy in the setting of pulmonary hypertension and Eisenmenger physiology is associated with a substantial maternal and fetal risk. Such patients are advised against pregnancy or to interrupt pregnancy before 10th gestational cut of week. Maternal mortality in the presence of Eisenmenger syndrome (ES) is reported to be 30 to 50% (3, 4) and increases further with associated complications. When these patients decide to begin or continue a pregnancy against advice, a coordinated multi-specialist care is mandatory. Over all fetal wastage is reported to be up to 75% (3). We are presenting a woman with severe pulmonary hypertension due to Eisenmenger syndrome treated during pregnancy, delivery and postpartum.

### Case Report:

A 34 year old woman was referred to our Hospital from obstetric and gynecology hospital for termination of pregnancy due to preeclampsia and Eisenmenger syndrome. At 32 week gestation, she presented with dyspnea, headache, palpitation, nausea and vomiting. The patient had history of blalock procedure with anastomosis between right pulmonary and subclavian arteries. On arrival at our hospital the patient's vital signs were as the follow: pales rate= 94, the systemic blood pressure which is obtained simultaneously, was 180/110 mmHg, respiratory rate= 22 and oxygen saturation of 88 % with oxygen delivered by nasal cannula .

The lab findings were as the follow: Hct = 51, Hb= 17.3, Plt = 193000, Cr= 1.3

TTE and contrast echo showed: a typical Ebstein anomaly, severely dysplastic TV, large size atrialized RV, very small functional RV, moderate to large size secundume type ASD (size=1.5 cm) with typical right to left shunt, and a severe PAH = 155 mmHg. No pericardial effusion have noticed.

8 hours later after admission the patient went on cesarean section surgery and a healthy girl was delivered. Magnesium sulfate was administered before and after delivery and the blood pressure was under control.

9 Dayes after delivery narrow QRS tachycardia with approximate rate of 160 was seen in patient with spontaneous termination. Electrophysiology consultation was done and  $\beta$  blockers with Calcium Channel Blockers were administered.

During hospitalization the patient developed facial nerve paralysis, dysarthria and vertigo were seen in brain CT scan and focal hypodense areas was seen in left cerebellar hemispheres was seen which MRI was recommended. In brain MRI a focal deficit was seen in left hemisphere of cerebellum which suggested the involvement left PCA and cerebellar infraction. The neurology consultation was recommended warfarin administration with INR range of 2-3 without any neurosurgery intervention. Due to frequent Psvt (Paroxysmal supra ventricular tachycardia) attacks, the patient undergone electrophysiological study 20 days after C/S. The diagnosis was WPW (Wolff-Parkinson-White syndrome) and the right free wall accessory pathway was ablated without complication. The patient was discharged with warfarin and follow up for INR control and neurology follow up was recommended.

### Discussion:

The common feature in all cases of Ebstein anomaly is apical displacement of the septal tricuspid leaflet in conjunction with leaflet dysplasia. Associated anomalies include PFO or ASD in approximately in 50% of patient, accessory conduction pathways in 25% (usually right sided) and occasionally, varying degrees of right ventricular out flow has seen with Ebstein anomaly depends on its severity.(5)

Eisenmenger syndrome, a term coined by Paul wood is defined as pulmonary vascular obstructive disease that develops as a consequence of a large preexisting left to right shunt such that pulmonary artery pressures approach systemic levels and the direction of the flow becomes bidirectional or right to left.(5)The most common modes of death are sudden death, CHF, pulmonary hemorrhages, pregnancy, and preoperative mortality after non cardiac surgery and infection causes (brain abscon and endocarditis) which account for most of the remaiing causes.(5)

Avoidance of pregnancy is of paramount importance in Eisenmenger syndrome. Non cardiac surgery should be performed only when it is absolutely necessary because of its association with high associated high mortality. Eisenmenger syndrome patients are particularly vulnerable to alterations in hemodynamic induced by anesthesia or surgery, such as minor decrease in systemic vascular resistance that can increase right to left shunting and possibly potentiate cardiovascular collapse. Additional risks of surgery include excessive bleeding, postoperative arrhythmia and deep venous thrombosis with paradoxical emboli. An air filter or bubble trap should be used for most intravenous lines in cyanotic patient. Early ambulation is recommended, and postoperative care in an intensive care unit setting is optimal. (5)

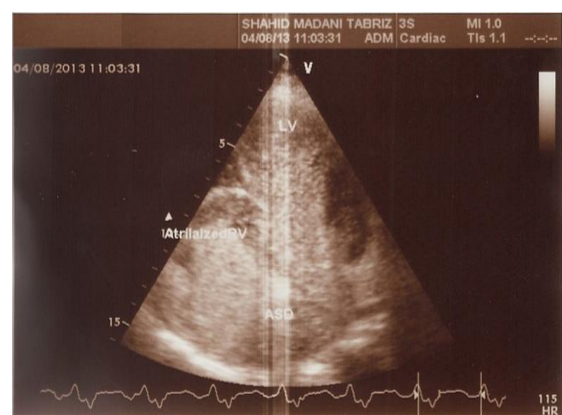
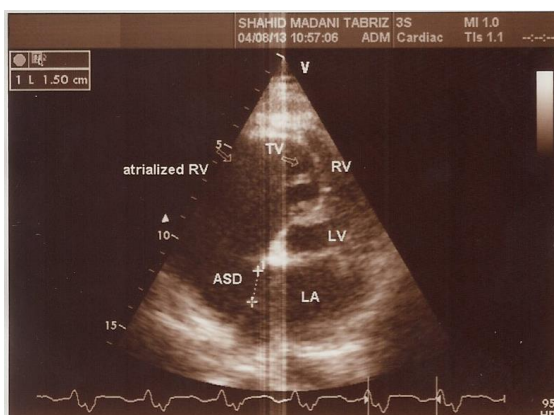
### Conclusion :

Although pregnancy has a high mortality in Eisenmenger syndrome, we have demonstrated a successful pregnancy early outcome early interfered in this setting which was complicated by later arrhythmia and CVA.

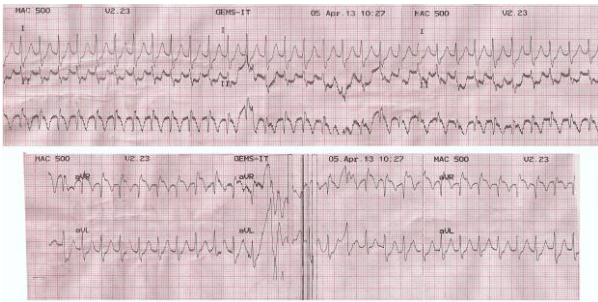
### Follow up :

4 months later after discharge, the patient was followed and there was no new problems in her situation and the child was doing fine.

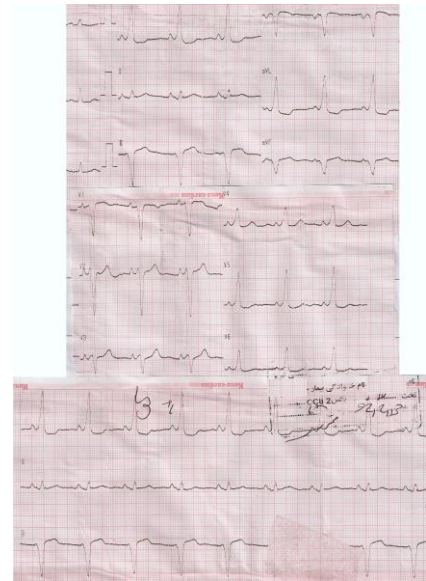
### Figures :



Contrast Injection



**Before Ablation (Psvt)**



**After Ablation (Sinus Rhythm)**

## References:

1. Jensen AS, Iversen K, Vejstrup NG, Hansen PB, Søndergaard L. Eisenmenger syndrome. (in Danish). 2009 ; 1270: 75.
2. Jones AM, Howitt G. Eisenmenger syndrome in pregnancy. 1965; 1627: 31.
3. Gleicher N, Midwall J, Hochberger D, et al. Eisenmenger syndrome and pregnancy. *Obstet Gynecol Surg.* 1979; 721:741.
4. Daliento L, Somerville J, Presbitero P, et al. Eisenmenger syndrome. Factors relating to deterioration and death. *Eur Heart J.* 1998; 1845: 55.
5. Robert o. Bonow, Douglasl.mann, Douglas p. zipes, peter libby. Braunwald,s Heart Disease. A textbook of cardiovascular Medicine. 2012 ;1770:77.